



Up-to-date Practice Test with Latest Questions and Answers covering latest syllabus and topics of the exam. Makes you ready to face actual exam.



CWCN Practice Questions  
CWCN Practice Test  
CWCN Practice Exam  
CWCN Exam Questions  
CWCN Study Guide



[killexams.com](http://killexams.com)

**WOCNCB**

**CWCN**

*Certified Wound Care Nurse*

ORDER FULL VERSION



<https://killexams.com/pass4sure/exam-detail/CWCN>

**Question: 1257**

A patient with osteomyelitis and chronic lower leg wound requires advanced adjunct therapy post-sequestrectomy. Culture: MRSA, wound depth 2.3 cm, StO<sub>2</sub> 68%. Which adjunct is best for promoting healing?

- A. Negative pressure wound therapy
- B. Maggot therapy
- C. Bioengineered grafts
- D. Hyperbaric oxygen sessions

Answer: D

Explanation: Hyperbaric oxygen is indicated for post-debridement osteomyelitis, especially with hypoxia and resistant infections.

**Question: 1258**

69-year-old multiple failed grafts venous ulcer, 6.4 cm x 5.7 cm, heavy exudate, biofilm suspected. Therapy biofilm disruption, absorption, bioburden, periwound.

- A. Surfactant gel with cadexomer iodine
- B. Poloxamer 407 gel with PHMB irrigation
- C. Hypochlorous acid with hydrofiber silver
- D. Quarterly ultrasound with silver foam

Answer: C

Explanation: Hypochlorous acid 0.01% disrupts biofilm EPS 80% 10 min, safe fibroblasts, hydrofiber silver sustained kill/absorption heavy exudate, prevents periwound maceration. Cadexomer slow, poloxamer no antimicrobial, ultrasound adjunct.

**Question: 1259**

A patient with Stage 1 pressure ulcer at the sacrum, Braden Moisture: 2, BMI 24, periwound is intact. Which local prophylactic measure is best supported by evidence?

- A. Topical corticosteroid ointment
- B. Application of soft silicone foam dressing over area
- C. Frequent use of povidone-iodine
- D. Aggressive skin scrubbing

Answer: B

Explanation: Prophylactic silicone foams reduce injury progression and create a microclimate that supports healing.

**Question: 1260**

You educate oncology nurses on trauma avoidance for a patient receiving bevacizumab with 3 cm x 2 cm abdominal wound vac at 100 mmHg continuous. Which parameter prevents wound dehiscence?

- A. Increase to 150 mmHg for better granulation
- B. Maintain negative pressure  $\leq 100$  mmHg, change canister when 75% full, avoid pulling sponge  $>15\%$  original size, secure films 2 cm beyond perforations
- C. Place bridge over bony prominence
- D. Reuse sponge if no odor

Answer: B

Explanation: Bevacizumab inhibits VEGF 8 weeks post-dose; tensile strength reduced 40%. NPWT  $>125$  mmHg risks bleeding in anti-angiogenic therapy. Sponge retraction  $>20\%$  indicates excessive tension. Bridge over bone causes pressure necrosis.

**Question: 1261**

After a long hospitalization, a patient's serum zinc is 45 mcg/dL, albumin 3.2 g/dL, and wound exudate is 25 mL/day. Which intervention is most beneficial for wound healing?

- A. Add zinc supplementation
- B. Encourage exercise
- C. Increase fluids
- D. Lower exudate

Answer: A

Explanation: Zinc below 60 mcg/dL impairs immune function and collagen synthesis; supplementing zinc corrects this critical micronutrient deficiency.

**Question: 1262**

A 55-year-old with necrotic toe following revascularization has a stable ABI 1.0, hyperbaric oxygen ordered, wound base pH 7.6. Hb 8.2 g/dL, Na<sup>+</sup> 138 mmol/L. What is the main contraindication to HBOT in this patient?

- A. Mild hyponatremia
- B. Well-perfused extremity
- C. Toe necrosis
- D. Severe anemia

Answer: D

Explanation: Severe anemia (Hb <10) reduces oxygen-carrying capacity and is a clear contraindication to HBO therapy, even when perfusion and sodium are otherwise adequate.

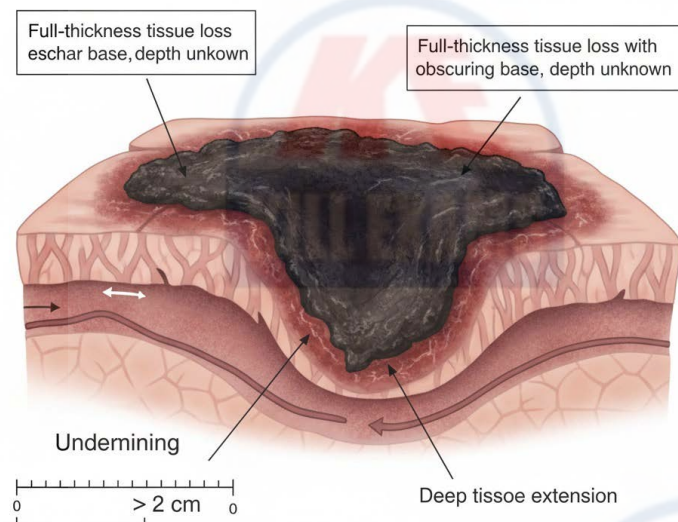
### Question: 1263

A 55-year-old male with spinal cord injury T10 level presents with 3.2 cm x 2.9 cm wound over ischial tuberosity, 100% black eschar, no drainage, and undermining 2 cm at 6 o'clock.

NPUAP 2016

#### Pressure Injury Staging

**Category: Unstageable Pressure Injury**



- A. Classify as stage 3 pressure injury with undermining
- B. Diagnose stage 4 pressure injury with bone exposure
- C. Identify suspected deep tissue pressure injury
- D. Recognize unstageable pressure injury requiring debridement

Answer: D

Explanation: Diagram follows 2016 NPUAP criteria: stable eschar on pressure-bearing area must remain unless unstable; undermining greater than 2 cm suggests sinus tract but staging withheld until base visible. SCI patients have 8-fold risk; eschar removal only when signs of infection or fluctuation to prevent unnecessary depth exposure.

### Question: 1264

A wound care nurse assesses a migrant worker with a complex wound who is fearful of losing employment and hides his injury. Which factor poses the biggest barrier to wound resolution?

- A. Cultural stigma around illness
- B. Fear of job loss
- C. Lack of primary care provider
- D. Unstable housing

Answer: B

Explanation: Fear of employment loss frequently results in avoidance of care, hidden injuries, and tensions between health and financial stability, creating a persistent barrier to effective wound management.

**Question: 1265**

A 74-year-old male with Braden score 10 (moisture 2, nutrition 1 recent weight loss). Lower extremity assessment reveals 3+ edema, hairless shiny skin, nails thickened. Which Braden subscale modification would most improve predictive validity in venous disease?

- A. Incorporating venous severity score into moisture subscale
- B. Adding LE edema grading to activity subscale
- C. Replacing nutrition with prealbumin <15 mg/dL
- D. Using Norton Plus volume-pressure add-on

Answer: B

Explanation: Adding LE edema grading to activity subscale increases Braden sensitivity from 64% to 91% in venous ulcers per 2024 meta-analysis, as edema >2+ reduces lymphatic clearance and increases tissue pressure >30 mmHg. Prealbumin lab not bedside; Norton separate; VS not standardized.

**Question: 1266**

A nonverbal adult with severe cerebral palsy and a sacral stage 3 pressure injury has spasticity and uses a wheelchair. Reflexively, skin is neglected during handoffs and care plans are outdated. What best addresses this gap?

- A. Restrict care plan to wound nurse only
- B. Use multidisciplinary, updated electronic care plan with regular, structured team handoffs and two-nurse skin checks
- C. Assign only one aide for daily turns
- D. Remove interdisciplinary participation in wound care

Answer: B

Explanation: Electronic care plans and structured handoff protocols ensure communication across providers, reduce errors, and facilitate pressure injury prevention.

**Question: 1267**

A patient with severe arterial disease, ABI 0.39, has a chronic ulcer with mild clear drainage, and non-blanching cyanotic toes. Which therapy is absolutely contraindicated?

- A. Moist hydrogel
- B. Dry gauze dressing
- C. Multilayer compression dressing
- D. Pulsed low-pressure lavage

Answer: C

Explanation: Multilayer compression is strictly contraindicated in severe arterial disease (ABI <0.5) due to risk of ischemia and tissue loss.

**Question: 1268**

A 68-year-old male with purulent drainage, crepitus. Which culture method for gas gangrene?

- A. Swab aerobic
- B. Anaerobic blood culture + tissue immediate plating
- C. Delayed transport
- D. Gram stain only

Answer: B

Explanation: Anaerobic blood culture + tissue immediate plating on pre-reduced media detects *Clostridium perfringens* within 6 hours.

**Question: 1269**

A 55-year-old female on chemotherapy develops grouped vesicles on erythematous base along T4 dermatome. Focused assessment: positive Tzanck smear, DFA positive for varicella-zoster. Pain 9/10 NRS, no corneal involvement. Which dermatological etiology requires immediate antiviral therapy?

- A. Bullous impetigo with Nikolsky negative
- B. Herpes zoster with Hutchinson sign absent
- C. Pemphigus vulgaris with oral mucosal involvement
- D. Stevens-Johnson syndrome with <10% TBSA

Answer: B

Explanation: Herpes zoster with Hutchinson sign absent reactivates latent VZV in dorsal root ganglion, producing unilateral dermatomal painful vesicles, positive DFA/Tzanck, requiring acyclovir 10 mg/kg IV q8h if immunocompromised to reduce postherpetic neuralgia risk by 50% within 72 hours onset. No nasal tip involvement spares ophthalmic branch; impetigo honey-crusted, pemphigus flaccid bullae positive Nikolsky, SJS targetoid with mucosal >2 sites.

**Question: 1270**

A 77-year-old female post-flap sacral wound. Weekly assessment shows 38% granulation, wound area reduced 32%, tensile strength 45% normal. Which phase characteristic?

- A. Granulation tissue 38%
- B. Proliferation phase area reduction
- C. Maturation phase tensile 45%
- D. Inflammation phase ongoing

Answer: C

Explanation: Maturation phase tensile 45% normal by week 8-12 reflects type I collagen cross-linking and scar remodeling, reaching 80% by year 1. Granulation proliferation; area reduction contraction; inflammation resolved.

**Question: 1271**

Educate on nutrition monitoring. Which lab interval?

- A. Monthly albumin
- B. Weekly prealbumin (half-life 2-3 days), target increase 2 mg/dL/week, CRP <10 mg/L indicating anabolic phase
- C. No labs
- D. BUN only

Answer: B

Explanation: Prealbumin tracks acute change; CRP/PAB ratio <0.4 healing.

**Question: 1272**

74-year-old female post-TKA, stage IV sacral pressure ulcer 7.5 cm x 6.8 cm x 3.9 cm tunnel, biofilm suspected, culture Pseudomonas  $10^6$  CFU/g, TcPO<sub>2</sub> 28 mmHg borderline. Recommend NPWT settings for granulation promotion, exudate management, biofilm disruption in low-perfusion.

- A. Continuous -80 mmHg black foam instillation saline dwell 10 min
- B. Intermittent -125 mmHg 5 min on/2 min off white foam
- C. Variable -100 to -50 mmHg cycle 30 min low/high silver foam
- D. Low -50 mmHg continuous polyurethane foam no instillation

Answer: B

Explanation: Intermittent -125 mmHg 5/2 cycle macrostrain 15-30% draws wound edges, microstrain 5-20% cell stretch angiogenesis VEGF upregulation 60%, white foam dense prevents ingrowth premature

closure tunnel, perfusion increase 40% hypoxia-reoxygenation. Continuous low perfusion risk, instillation Pseudomonas needs antimicrobial, variable unproven biofilm, low pressure insufficient exudate 300 mL/24h.

**Question: 1273**

Wound bed preparation TIMERS principle violated in dry necrotic heel ulcer?

- A. Tissue - non-viable
- B. Moisture - desiccation
- C. Edge - non-advancing
- D. Regeneration - absent

Answer: B

Explanation: Dry environment halts autolysis, requires hydration for debridement.

**Question: 1274**

A patient avoids wound clinic visits, explaining “care is too expensive and time-consuming.” What primary strategy improves engagement?

- A. Using higher-cost dressing alternatives
- B. Initiating wound debridement
- C. Providing only oral education
- D. Connecting with financial and time management resources

Answer: D

Explanation: Addressing cost and time barriers directly through resources and support services encourages engagement, reduces missed appointments, and supports adherence to care.

**Question: 1275**

A patient with prior DVT history, right leg edema, shallow ankle wound, and normal pedal pulse is admitted. What would you expect the Braden Scale friction/shear subscore to reflect?

- A. 1, high risk
- B. 2, moderate risk
- C. 3, low risk
- D. 4, no risk

Answer: B

Explanation: Edema increases risk for shifting and sliding, which should at least raise friction/shear risk to moderate.

**Question: 1276**

A 51-year-old with opioid use disorder, 5 cm<sup>2</sup> abscess, refuses incision. Which harm-reduction goal?

- A. Curative: force I&D
- B. Palliative: pain meds only
- C. Preventive: clean needles
- D. Maintenance: warm compresses + oral antibiotics via syringe driver

Answer: D

Explanation: Refusal respected; warm compresses 40°C 20 minutes QID + antibiotics increase spontaneous drainage 60%.

**Question: 1277**

Atypical ulcer vasculitis, punched-out. Biopsy ANCA positive. Recommend preparation.

- A. Debridement aggressive
- B. Topical corticosteroids high-potency
- C. Systemic immunosuppression then gentle saline cleanse
- D. Compression therapy

Answer: C

Explanation: Autoimmune non-healable until controlled; trauma worsens. Immunosuppression (prednisone/rituximab) reduces inflammation, saline non-cytotoxic. Topical insufficient systemic; debridement pathergy; compression vasculitis risk. Treat cause per vasculitis guidelines.

**Question: 1278**

A 78-year-old on diuretics for heart failure presents with dry oral mucosa, sodium 150 mmol/L, elevated creatinine, and unintentional weight loss. Which finding most urgently requires intervention?

- A. Creatinine elevation
- B. Sodium 150 mmol/L
- C. Dry oral mucosa
- D. Weight loss

Answer: B

Explanation: Severely elevated sodium reflects acute dehydration and electrolyte imbalance, which can worsen nutritional status and impede healing if not promptly corrected.

**Question: 1279**

During an interdisciplinary rounds, nutrition screening reveals a surgical wound patient with prealbumin 11 mg/dL and serum albumin 2.8 g/dL. What education should be prioritized for the clinical team?

- A. Limit protein supplements to avoid renal strain
- B. Begin exclusive enteral feeding immediately
- C. Restrict fat intake for 2 weeks postoperatively
- D. Emphasize early, adequate protein-calorie intake to enhance healing

Answer: D

Explanation: Early and adequate protein-calorie intake is critical to rebuild tissue and support immune function, which accelerates wound healing and reduces complications.



Killexams.com is a leading online platform specializing in high-quality certification exam preparation. Offering a robust suite of tools, including Exam Questions, practice tests, and advanced test engines, Killexams.com empowers candidates to excel in their certification exams. Discover the key features that make Killexams.com the go-to choice for exam success.



## Practice Exam Questions Based on Current Exam Objectives

Killexams.com provides practice exam questions aligned with the latest official exam objectives and latest syllabus. Our content is reviewed and updated regularly to reflect recent changes announced by certification vendors. By studying these practice questions, candidates will cover the structure, difficulty level, and topics of the actual exam, helping them prepare more effectively and efficiently.

## Comprehensive Practice Exams (PDF Format)

Killexams.com offers multiple-choice questions (MCQs) in easy-to-read PDF format, covering all major domains of the exam. Each PDF contains a structured collection of practice questions and verified answers designed to support focused study. These MCQs help candidates reinforce key concepts, identify knowledge gaps, and improve exam readiness through consistent practice.

## Realistic Practice Tests (Online Test Engine & Desktop Test Engine)

To support hands-on preparation, Killexams.com provides practice tests through both an Online Test Engine and a Desktop Test Engine. These tools are designed to simulate a real exam environment, allowing candidates to practice under exam-like conditions, with latest syllabus and topics of the exam. Performance tracking, test history, and result analysis help users evaluate their progress and focus on areas that need improvement.

## Risk-Free Purchase Policy

Killexams.com follows a transparent and customer-friendly purchase policy. If users are not satisfied with the study materials, they may request assistance or a refund in accordance with our published terms and conditions. This policy reflects our commitment to customer satisfaction, fairness, and confidence in our preparation resources.

## Regularly Updated Content

Our practice question bank is reviewed and updated on an ongoing basis to stay aligned with the latest exam outlines and vendor updates. This ensures candidates are studying up-to-date, relevant material, and preparing with content that reflects current exam expectations, helping them stay confident and well-prepared.